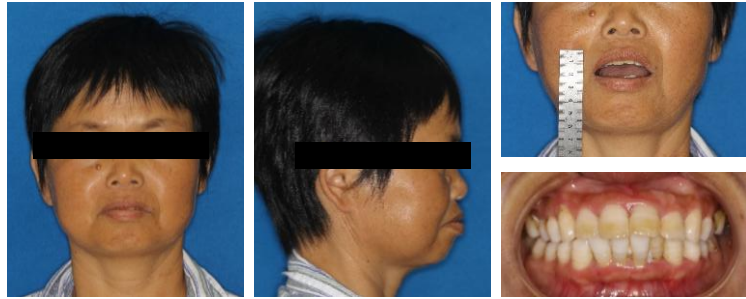


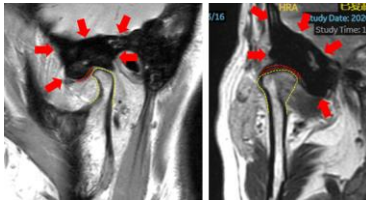
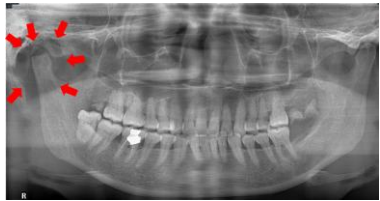Skull base-fossa prosthesis that preserves the non-diseased condyle

Preoperative



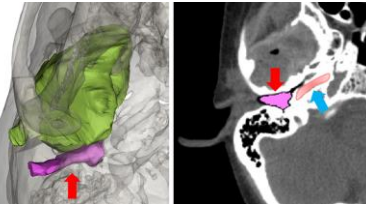
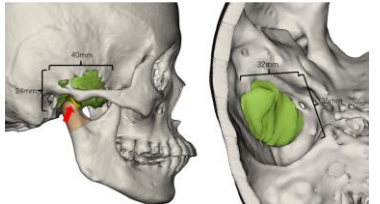
Panoramic X-ray

TMJ MRI (undefected disc and condyle)



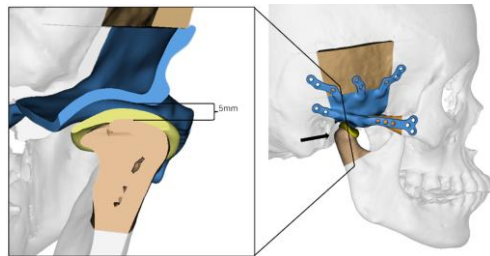
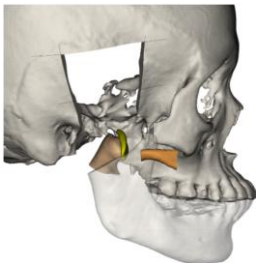
CT showed a skull base perforation

Tumor to ear canal and internal carotid



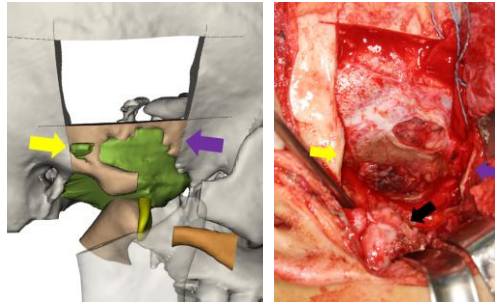
Defect model after resection

Skull base-fossa prosthesis design

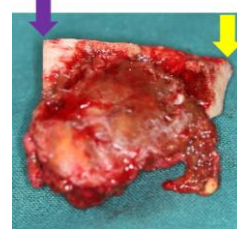


Operation

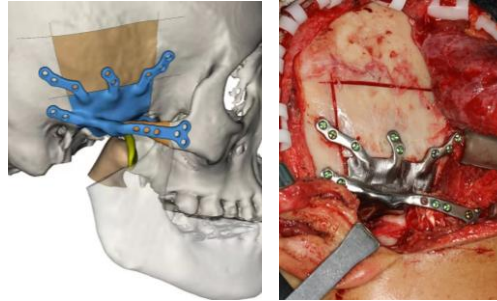
① Skull base osteotomy



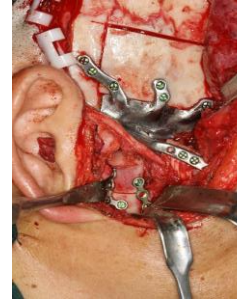② Tumor



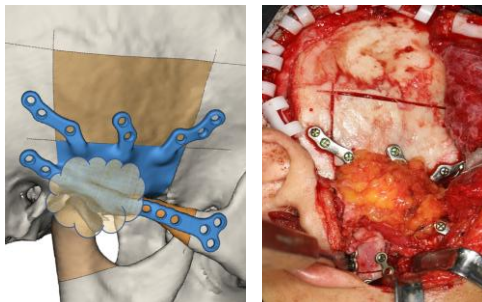
③ Prosthesis installation



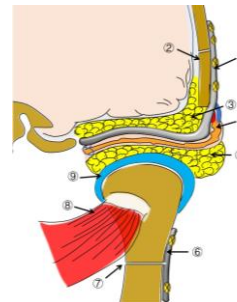
④ Condylar fixation



⑤ Abdominal fat graft

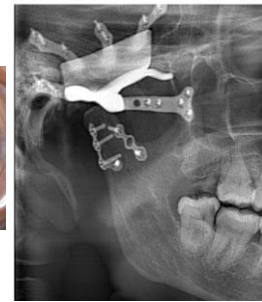
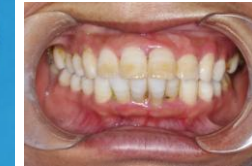
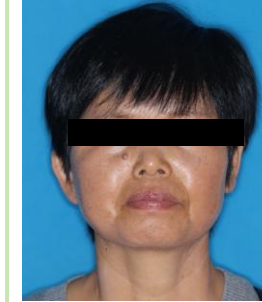⑥ Schematic diagram



Postoperative

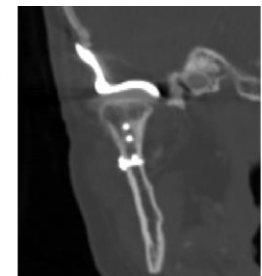
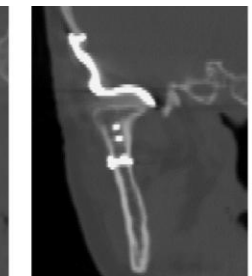
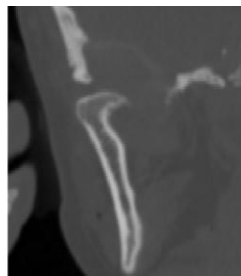
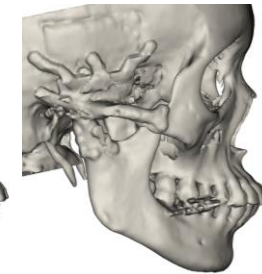
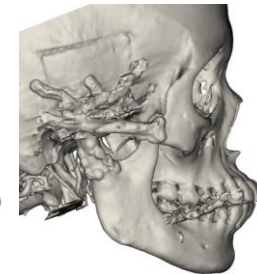
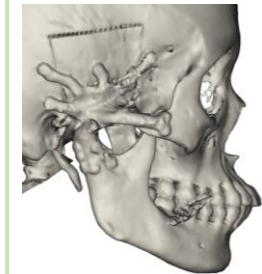
Five years after surgery



Immediate postoperative CT

One year postoperative CT

Five year postoperative CT



Comparison of condylar status showing no resorption of the condyle and good remodeling after surgery